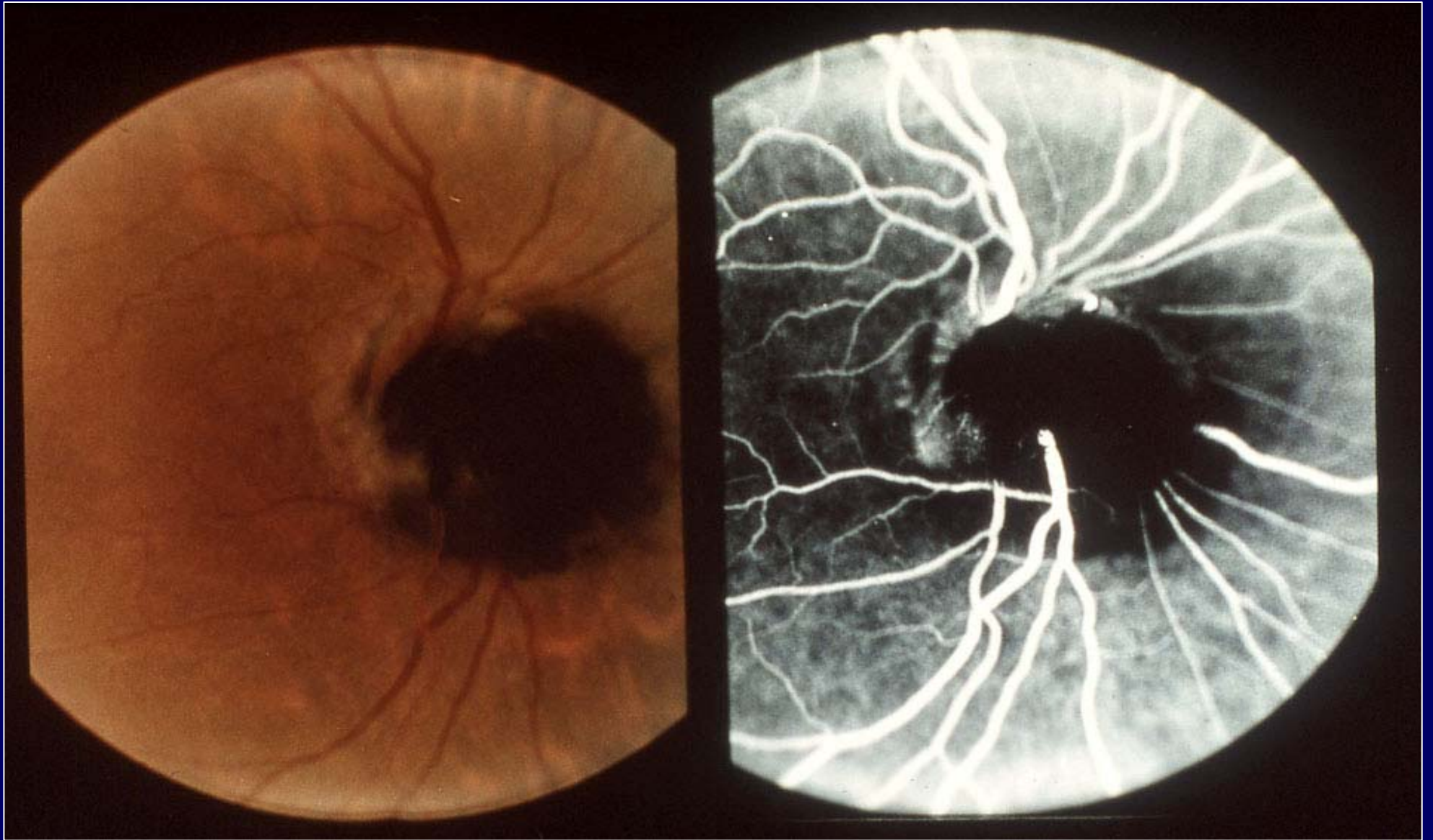
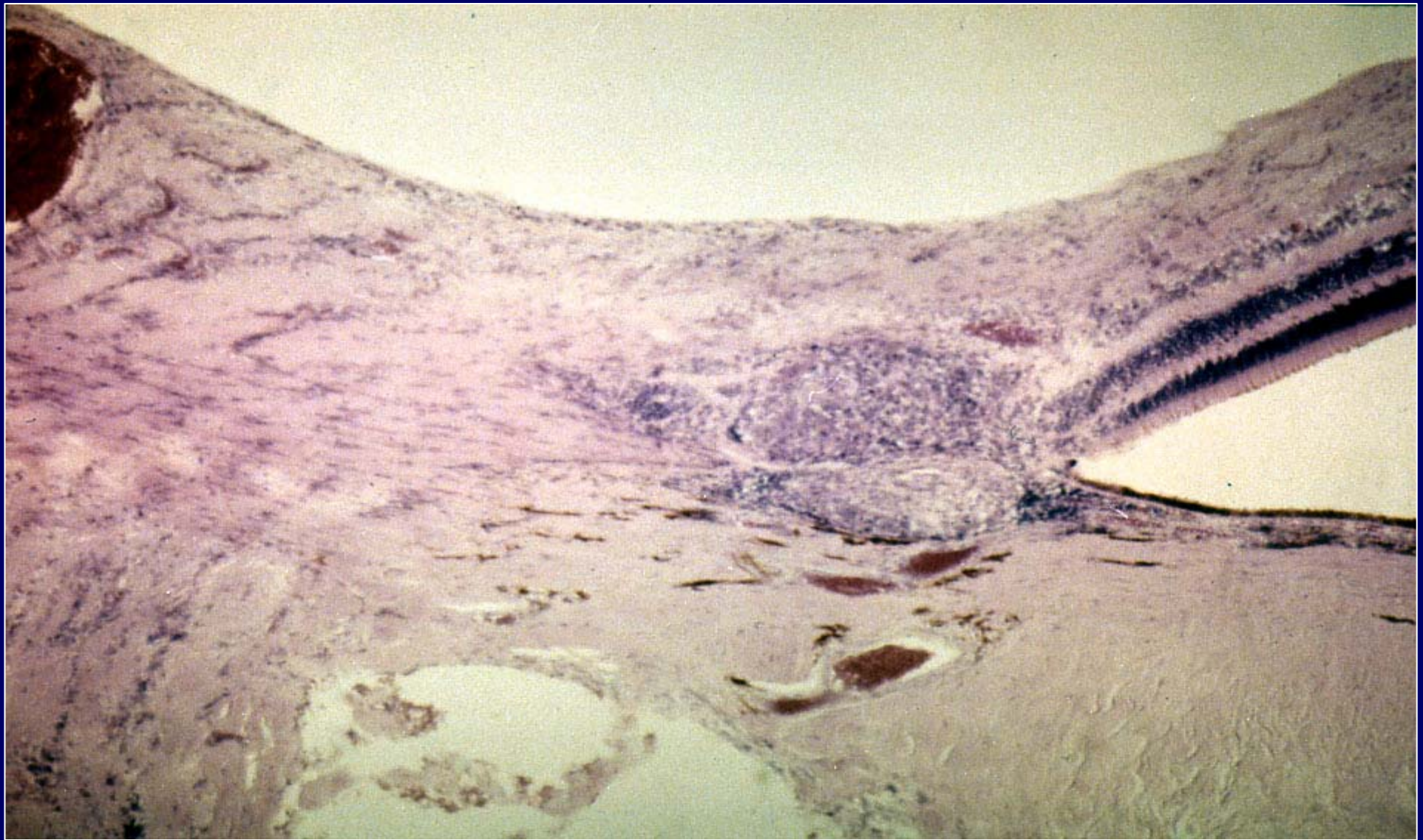


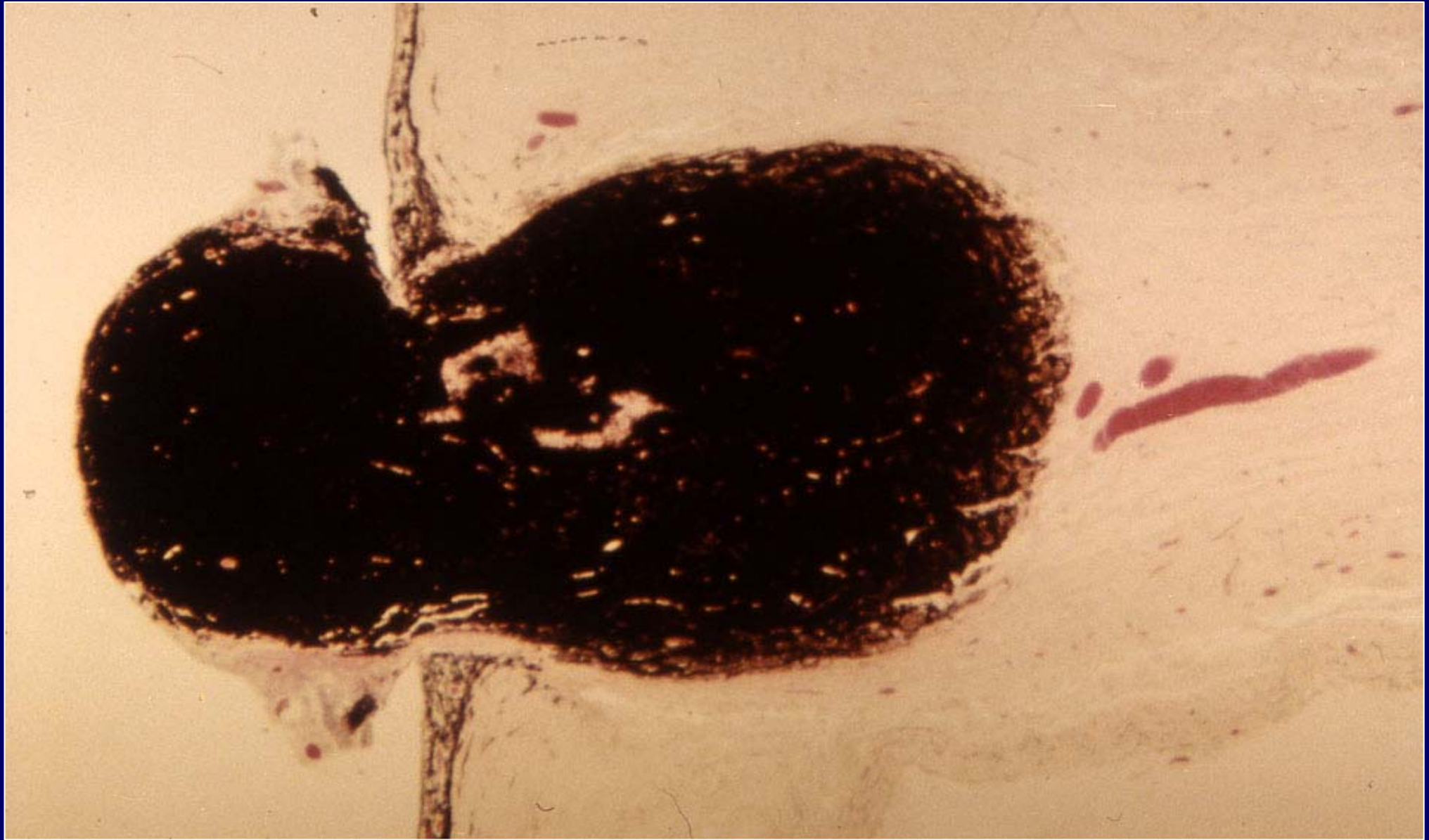Tumori del nervo ottico



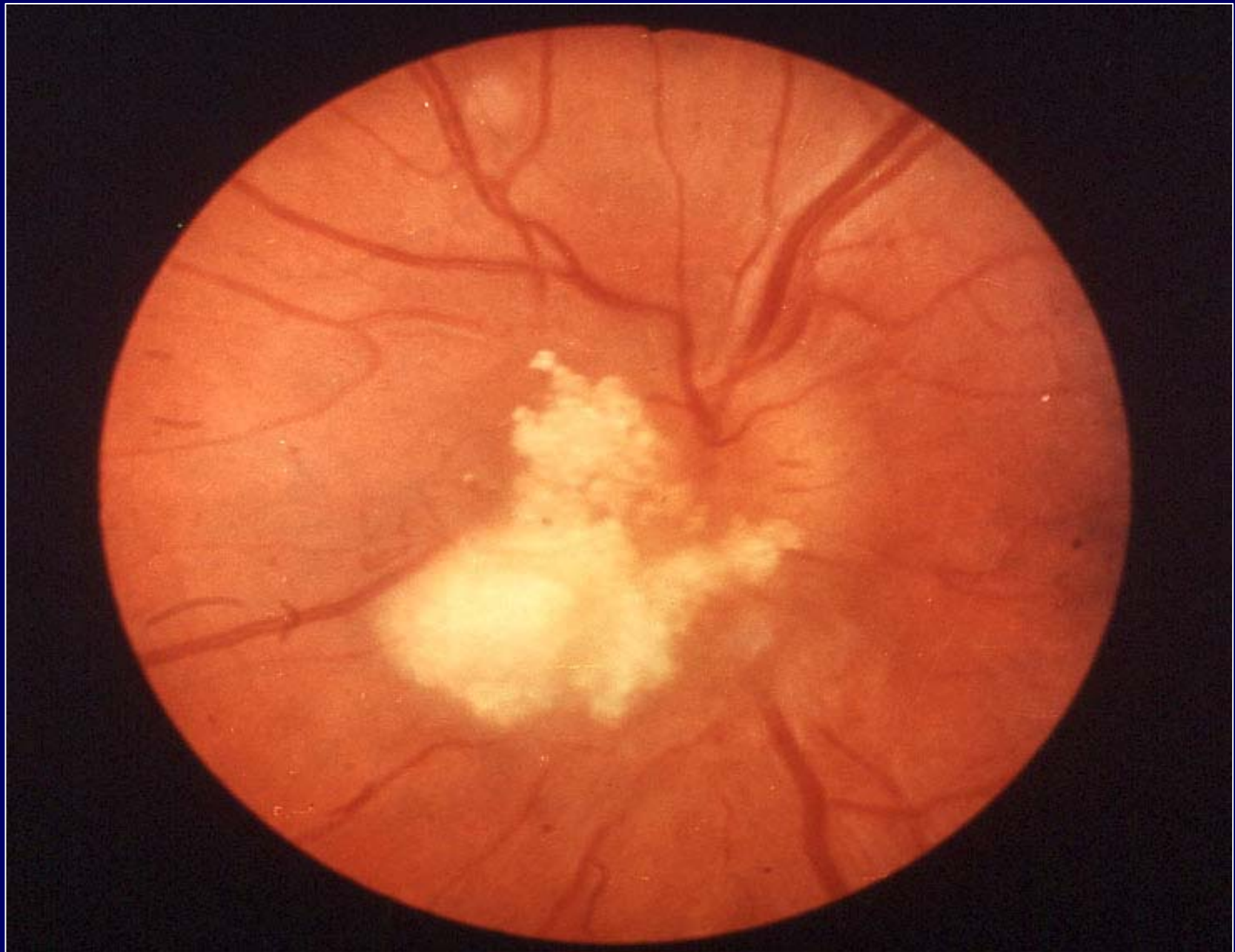
Melanocytoma



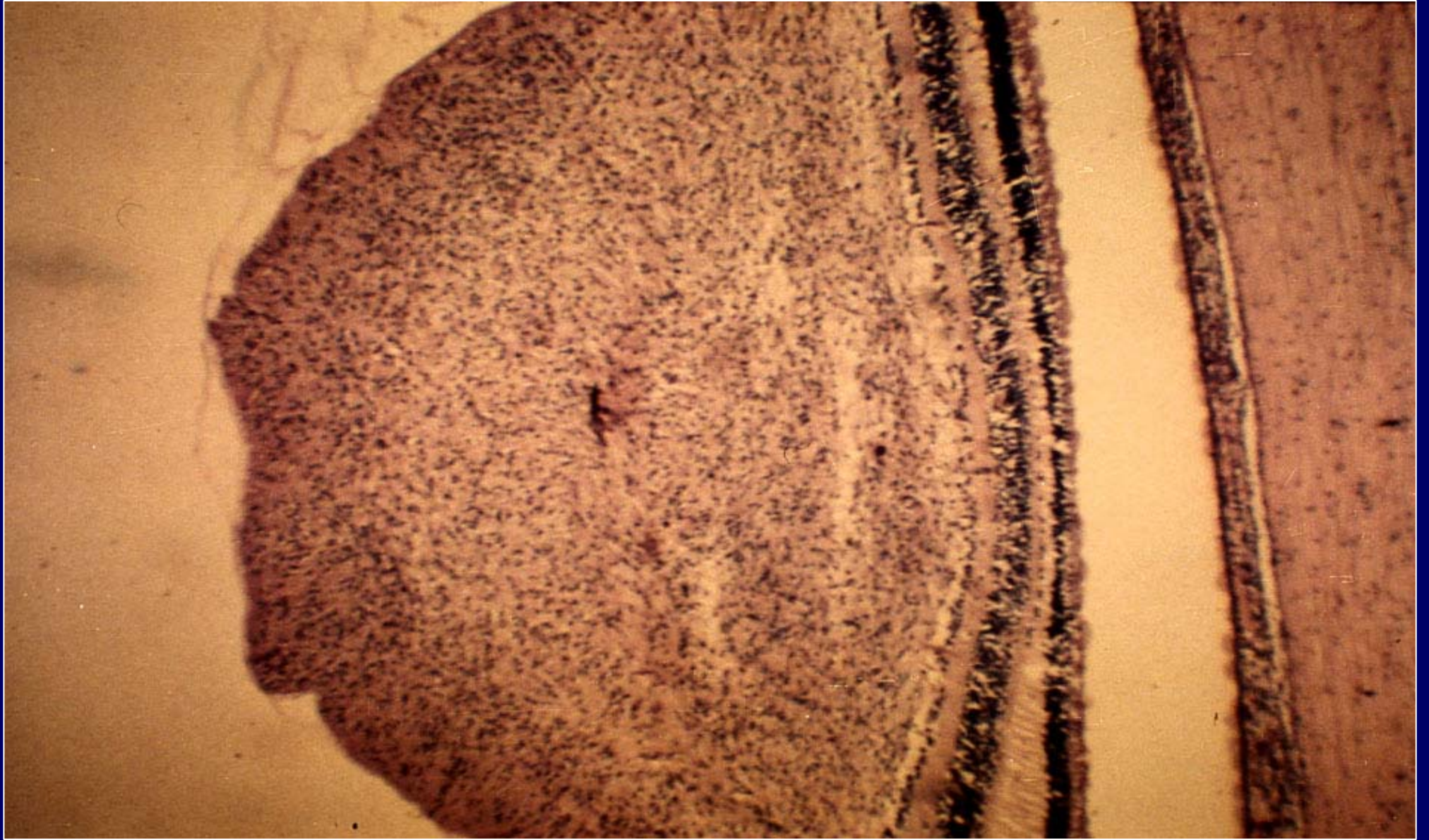
**Histopathology of a sarcoid granuloma in
the optic nerve head**



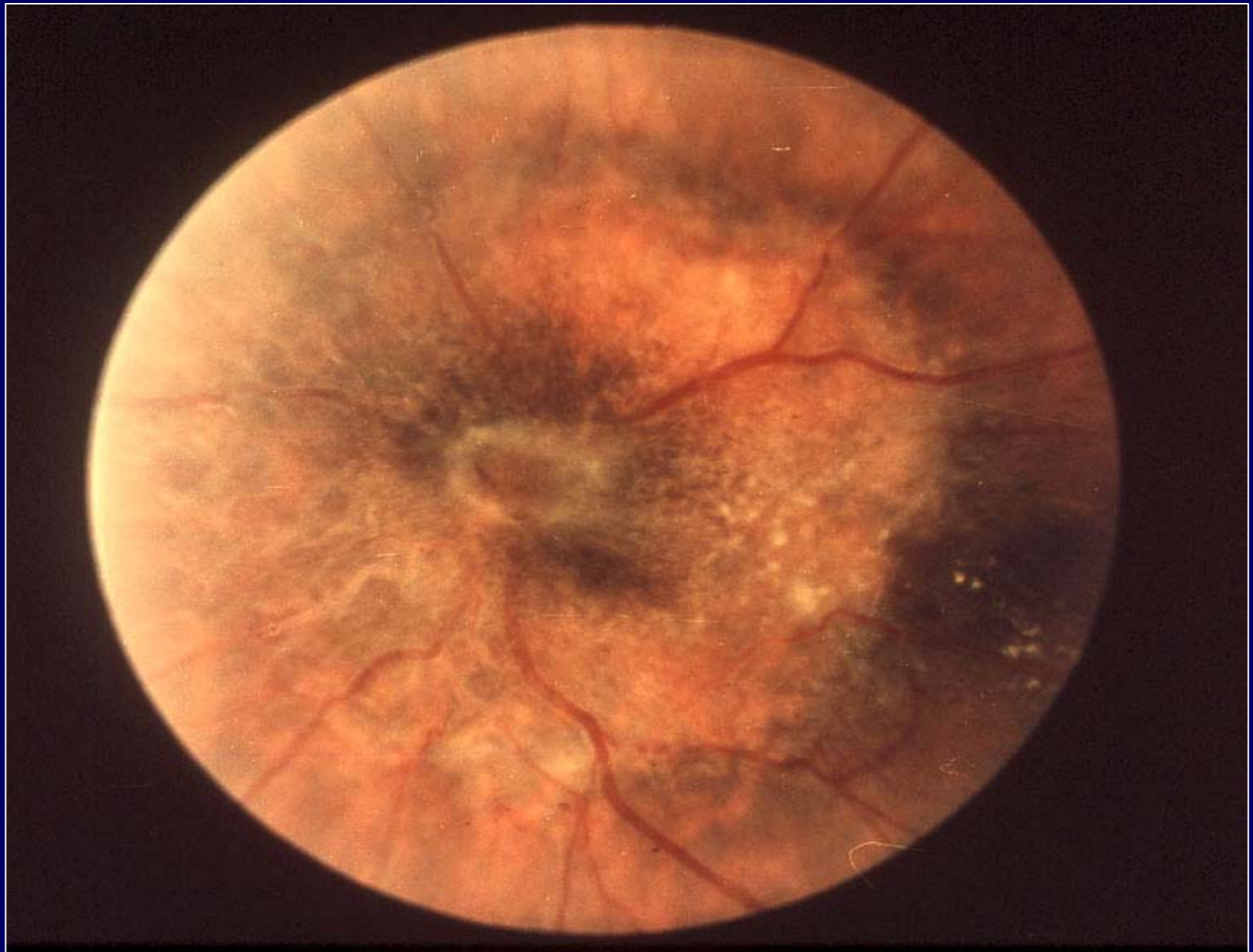
Melanocytoma: histopathology



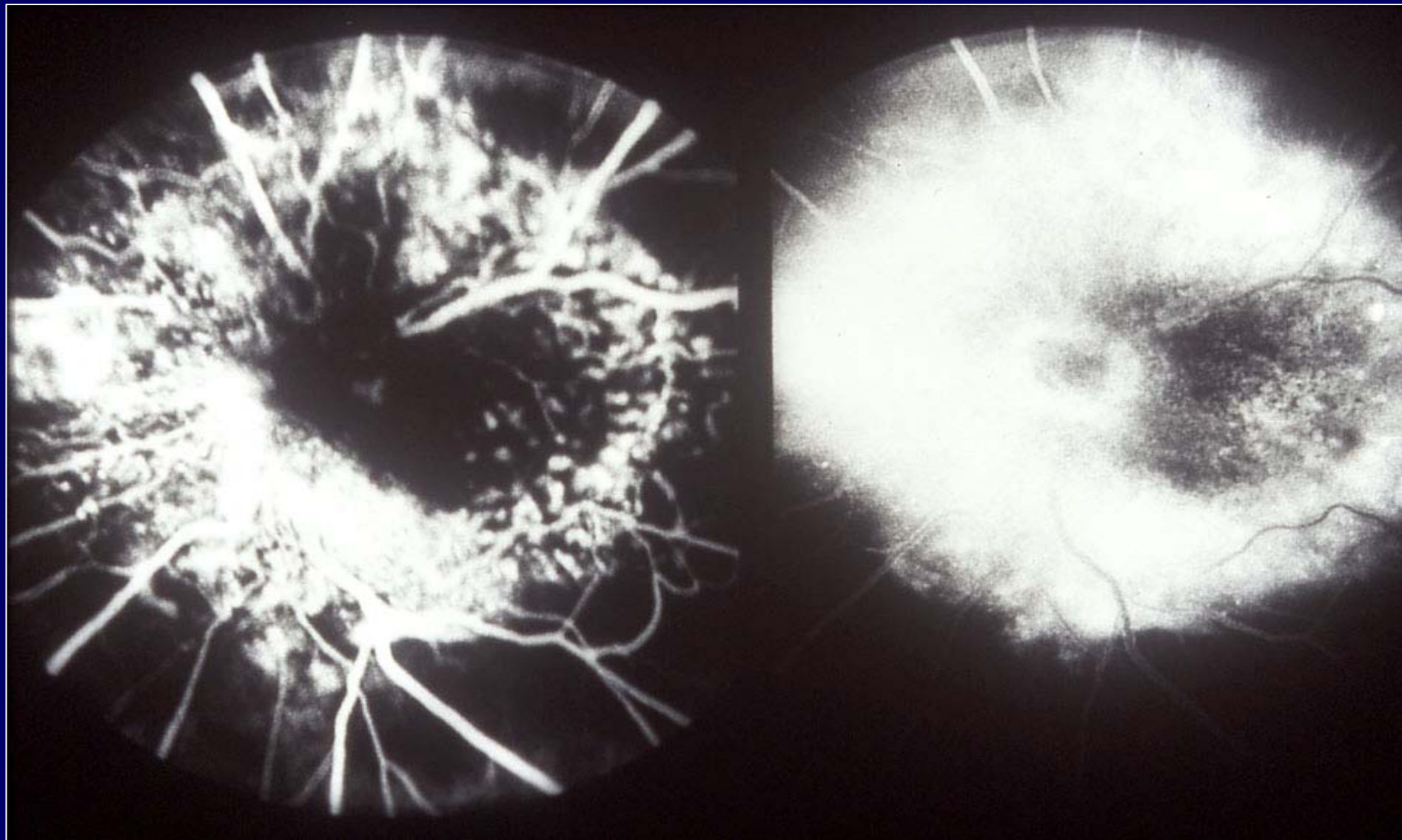
Astrocytic hamartoma



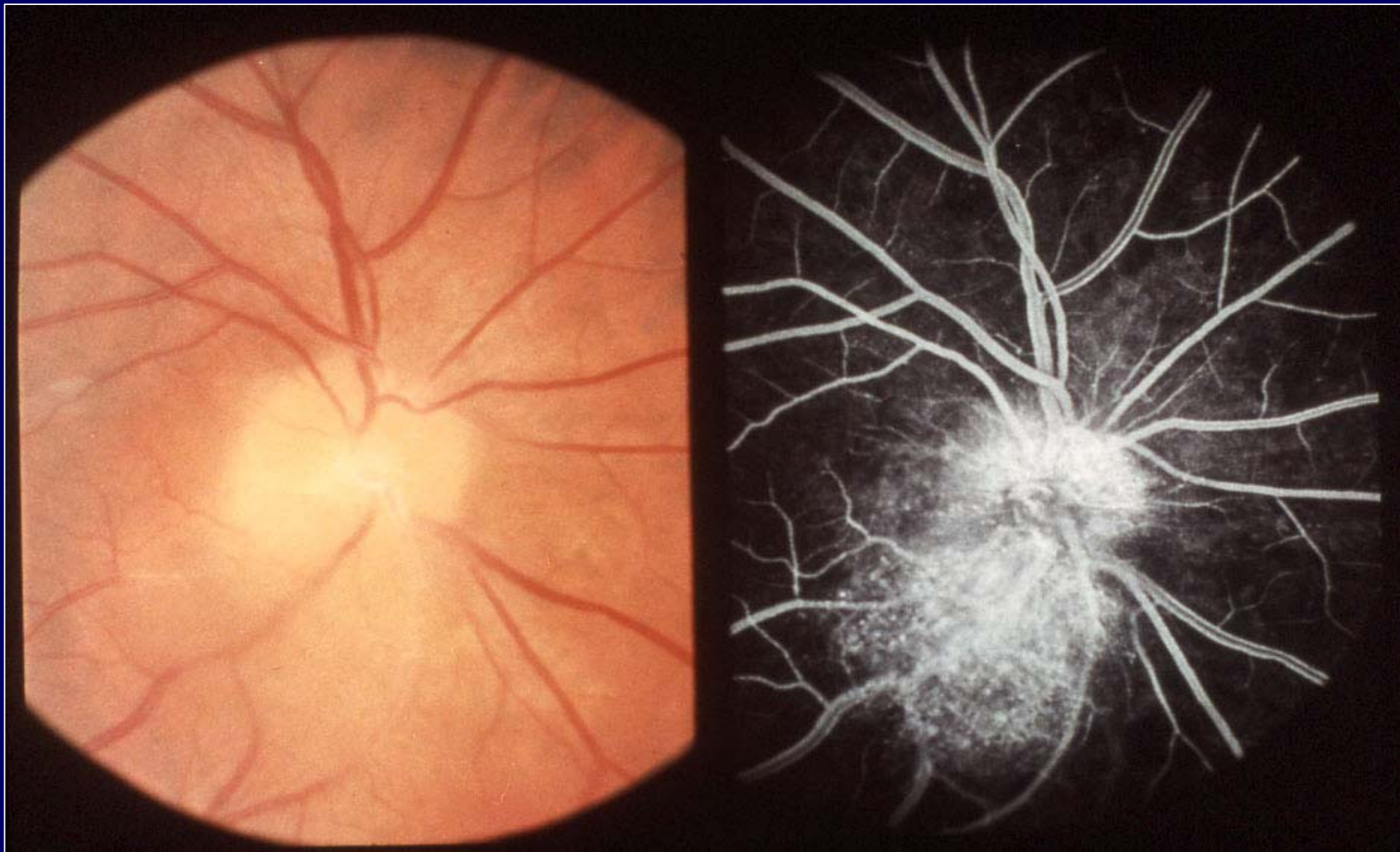
Astrocytic hamartoma: histopathology



Pigmented epithelial hamartoma



Pigmented epithelial hamartoma:
fluorescein angiogram



Capillary angioma of the optic disc