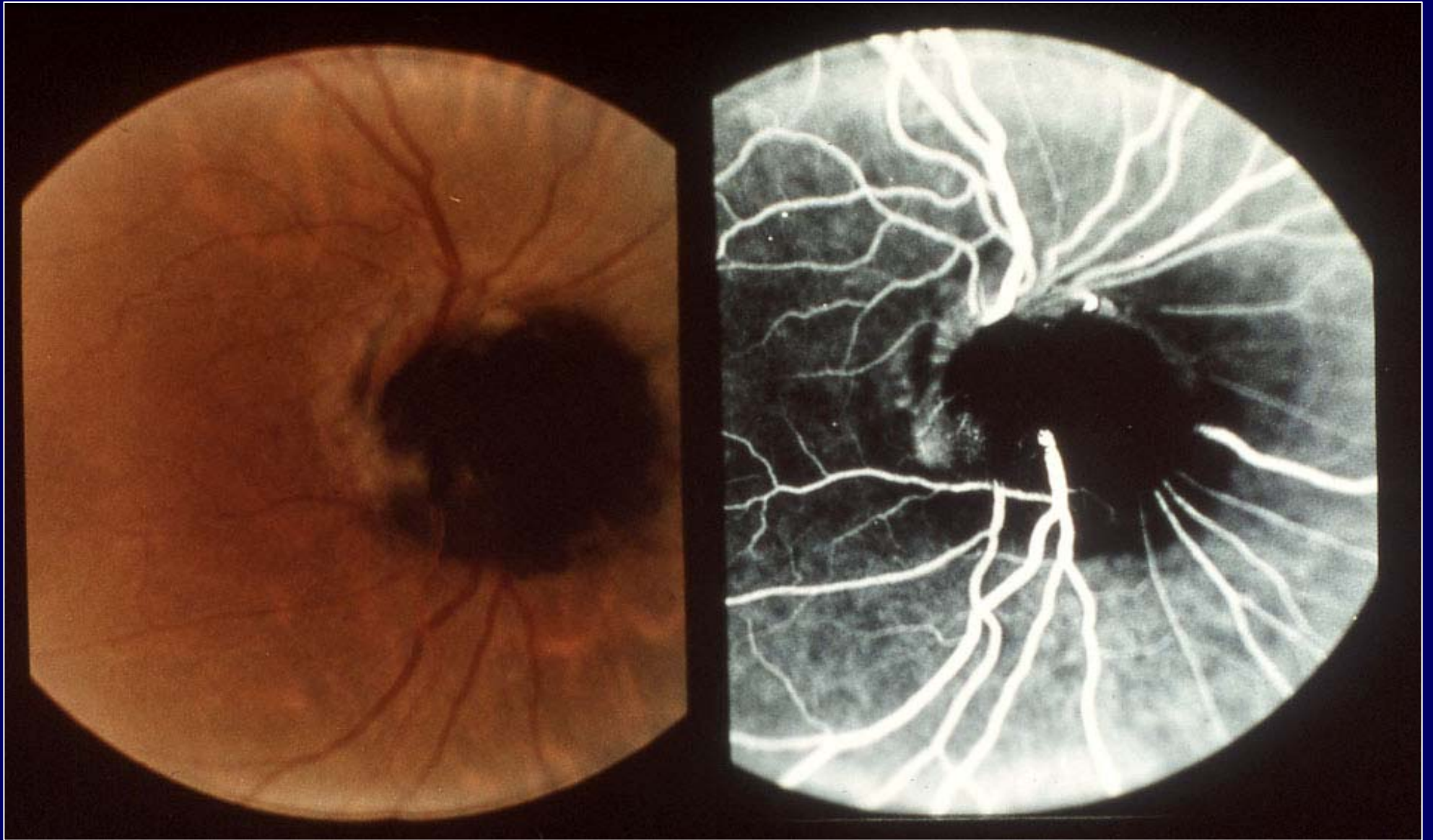
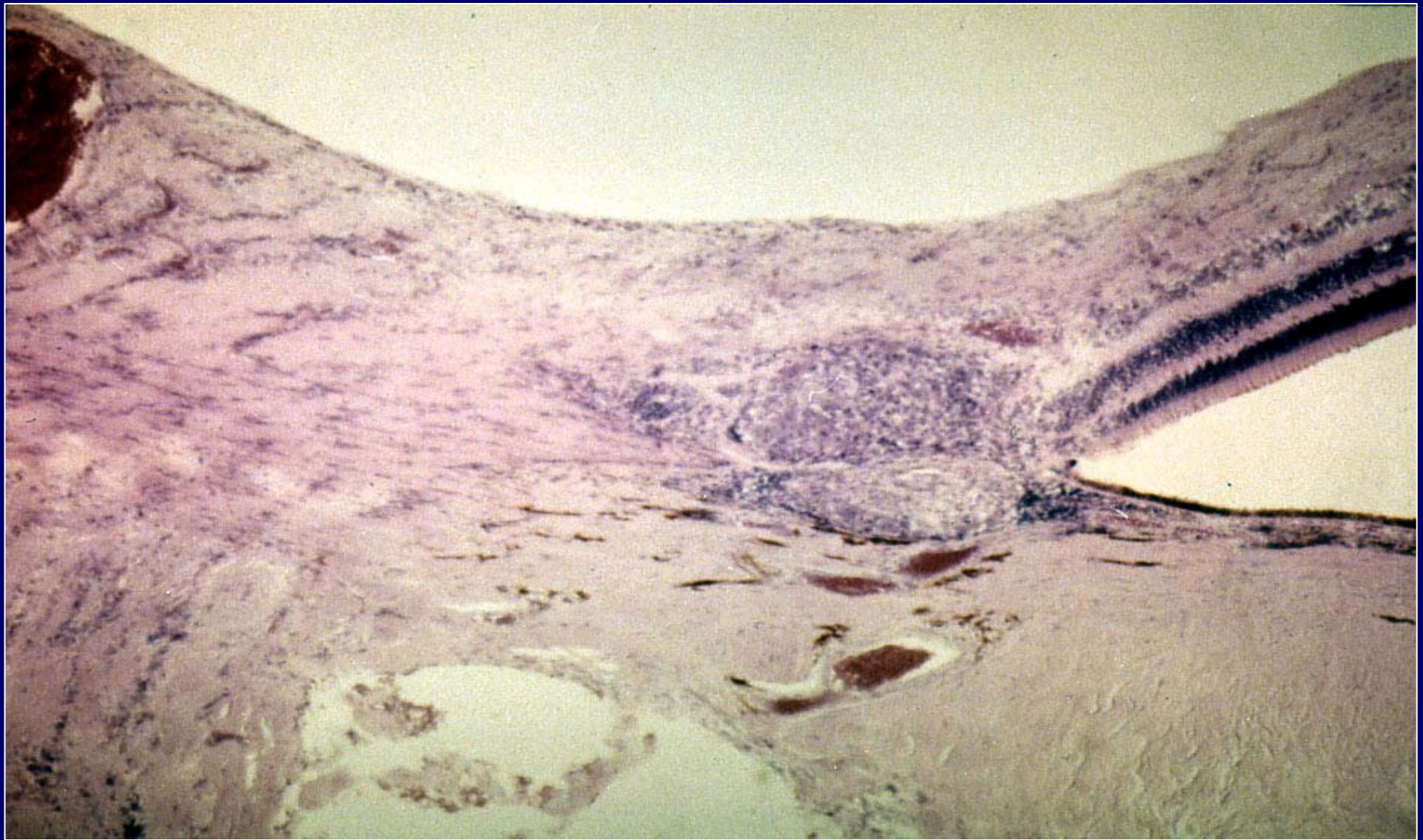


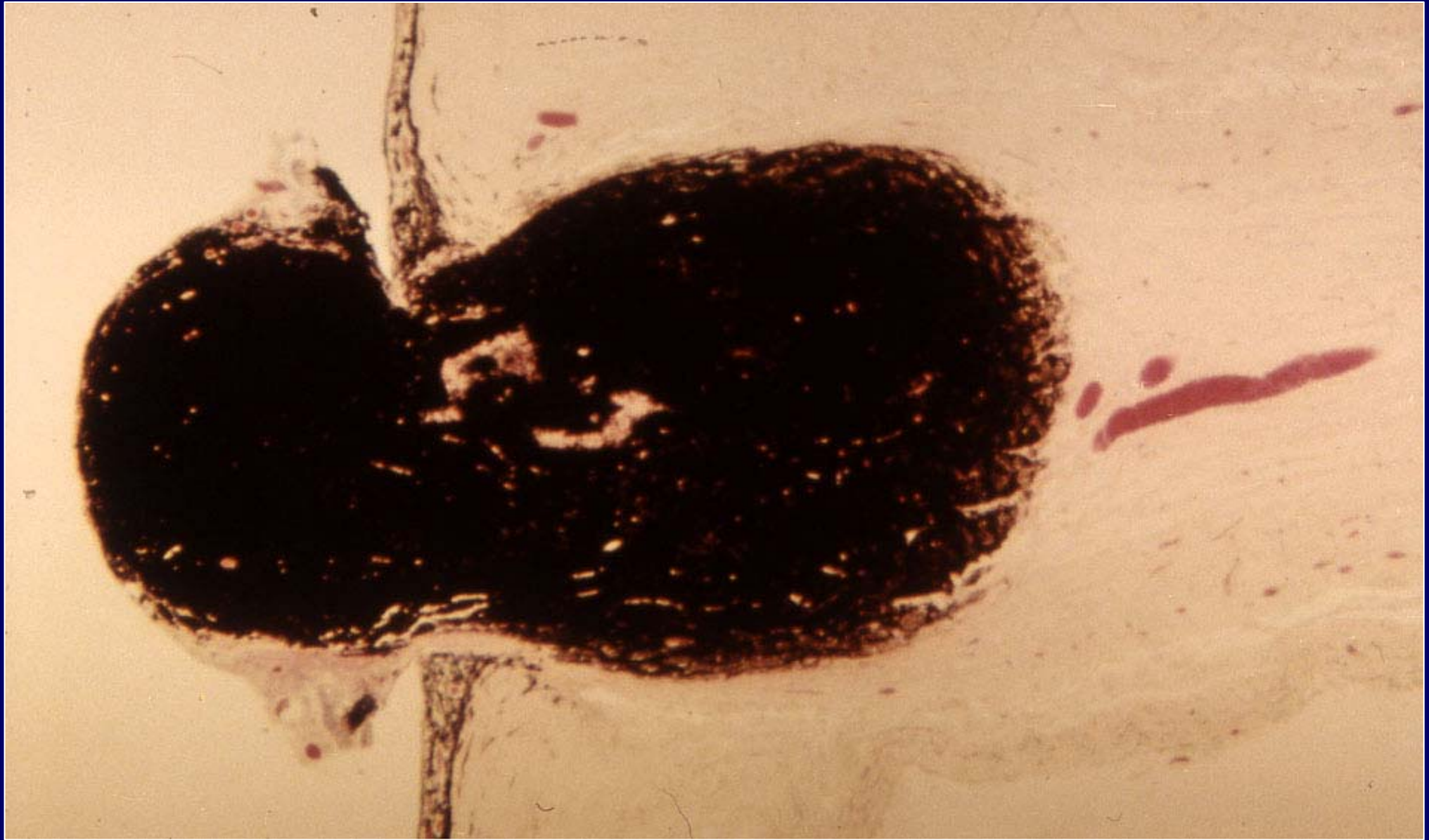
# **Tumori del nervo ottico**



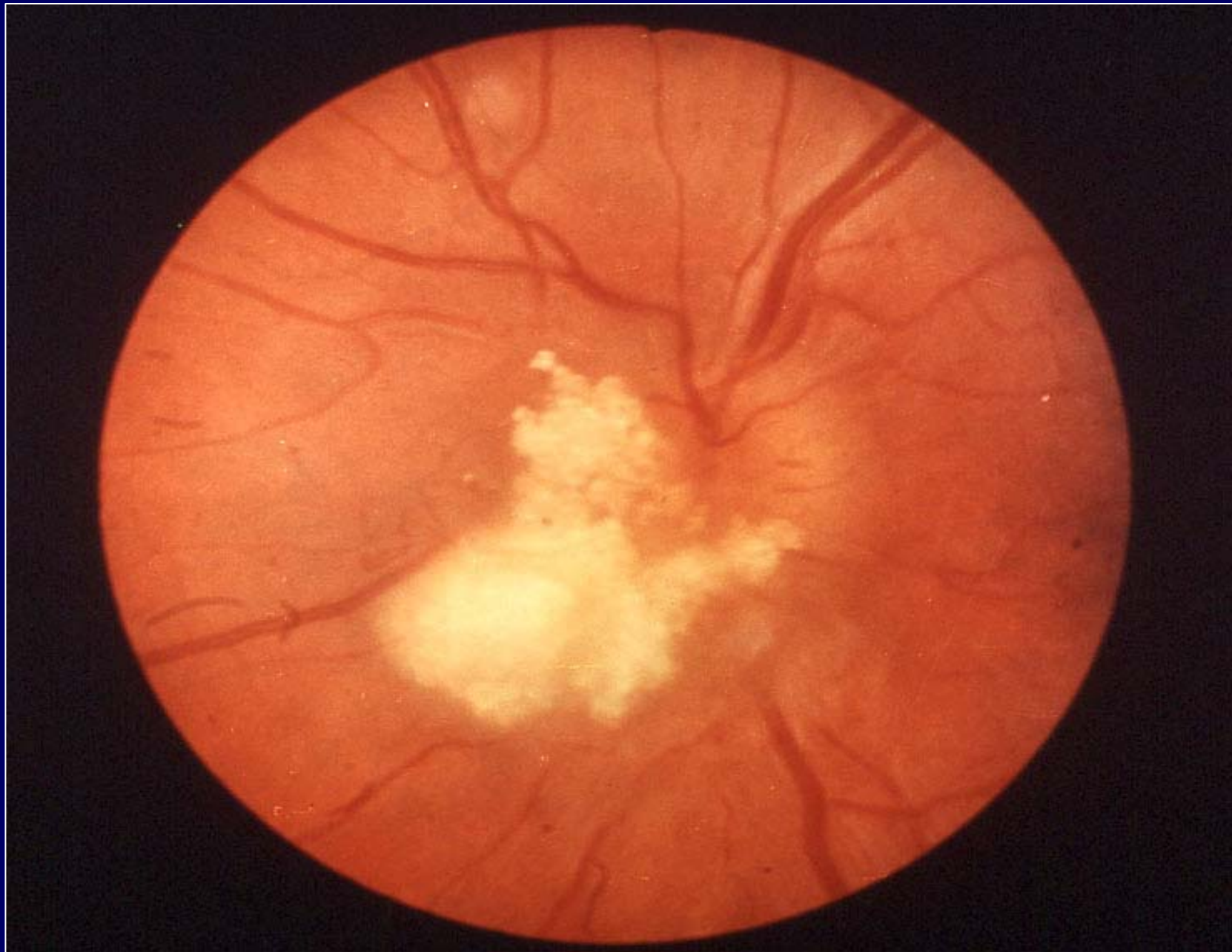Melanocytoma



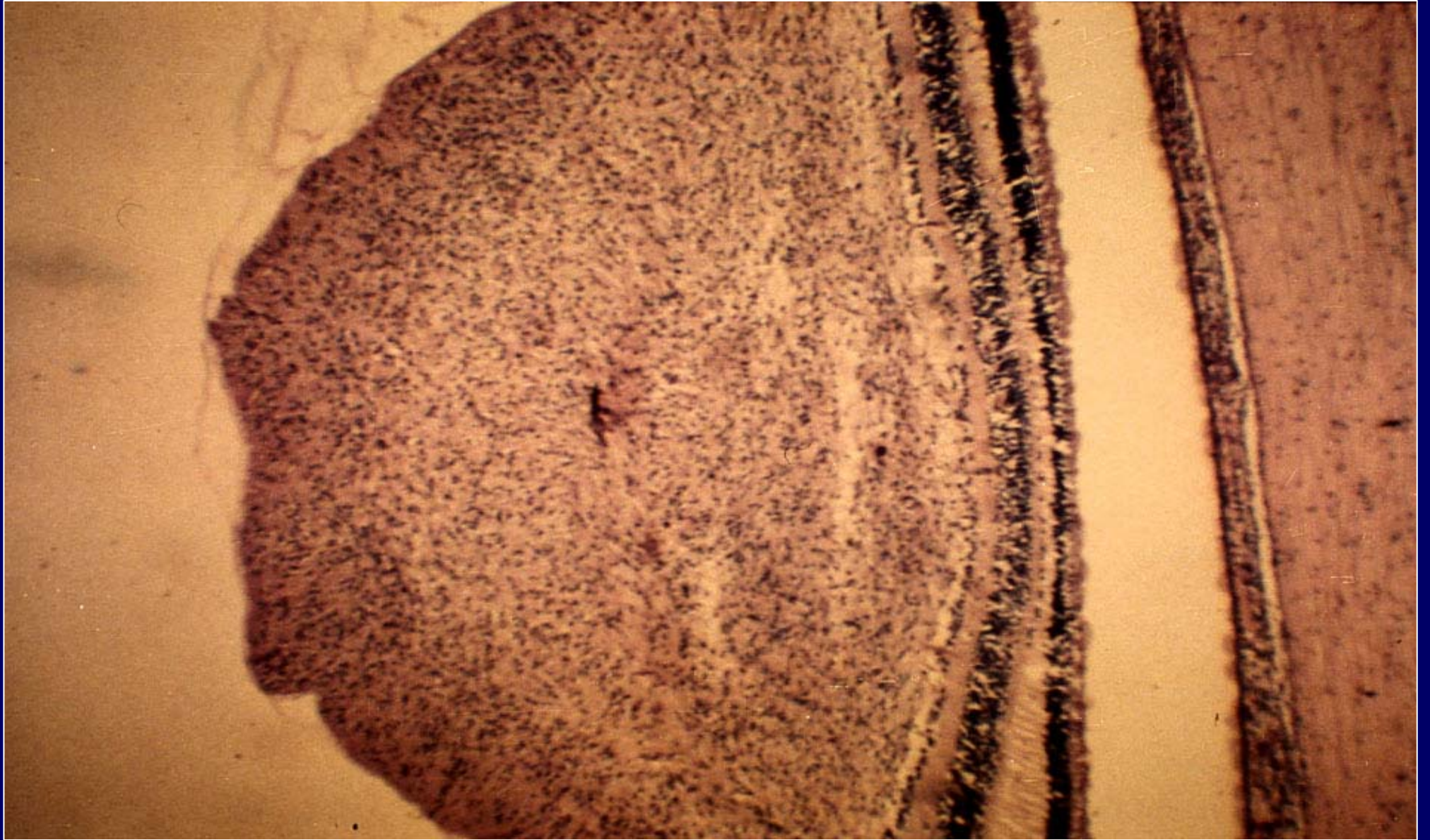
**Histopathology of a sarcoid granuloma in  
the optic nerve head**



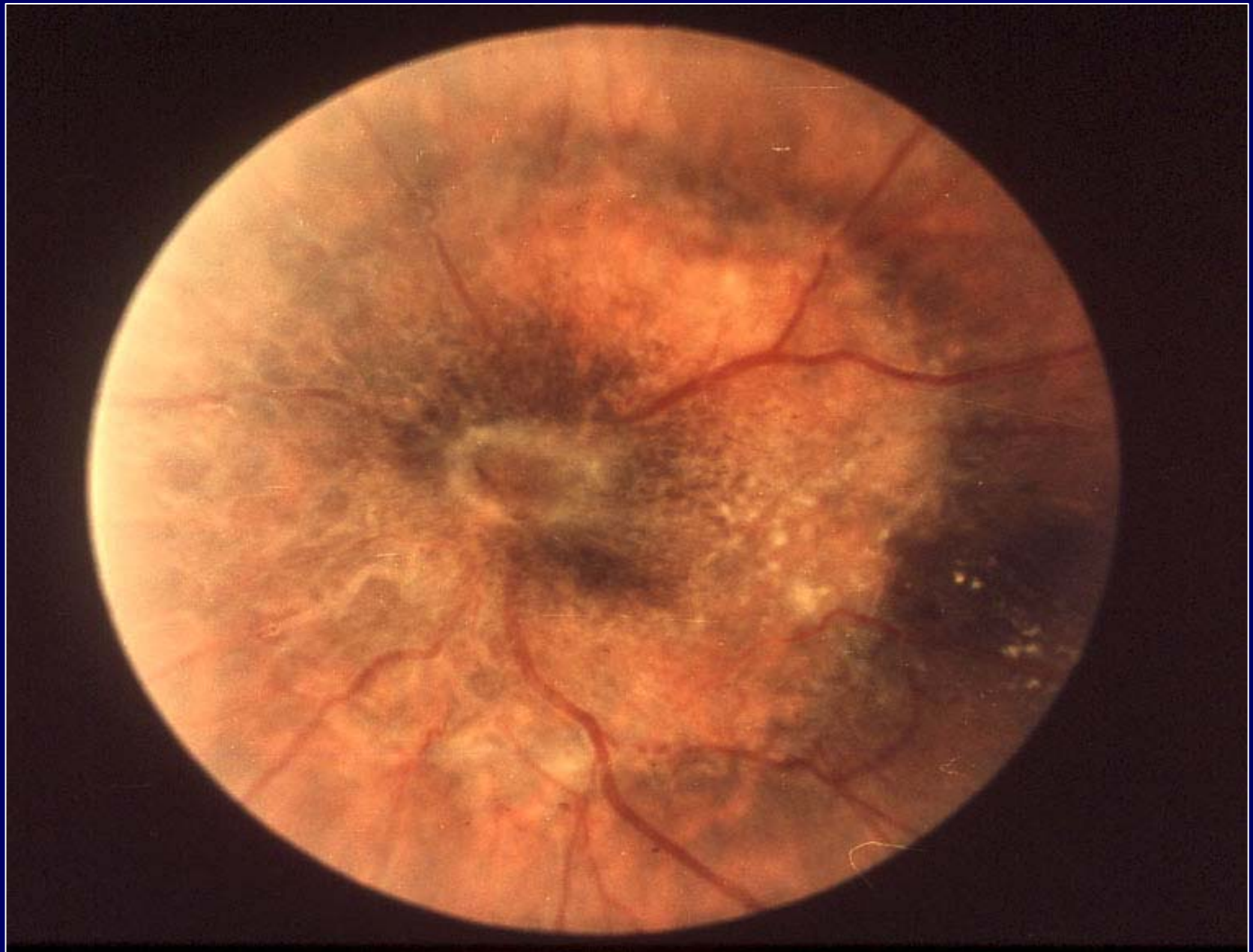
Melanocytoma: histopathology



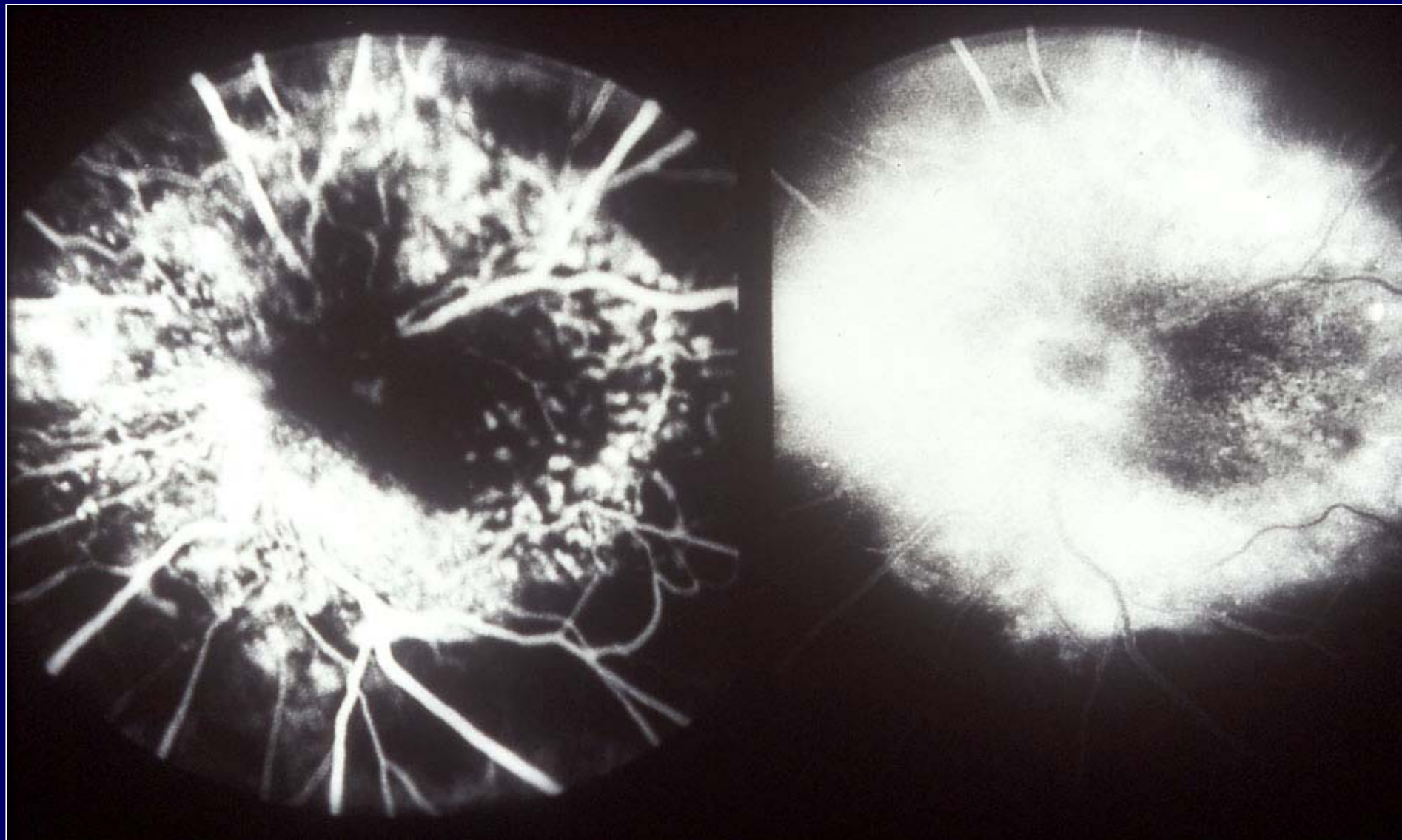
Astrocytic hamartoma



Astrocytic hamartoma: histopathology

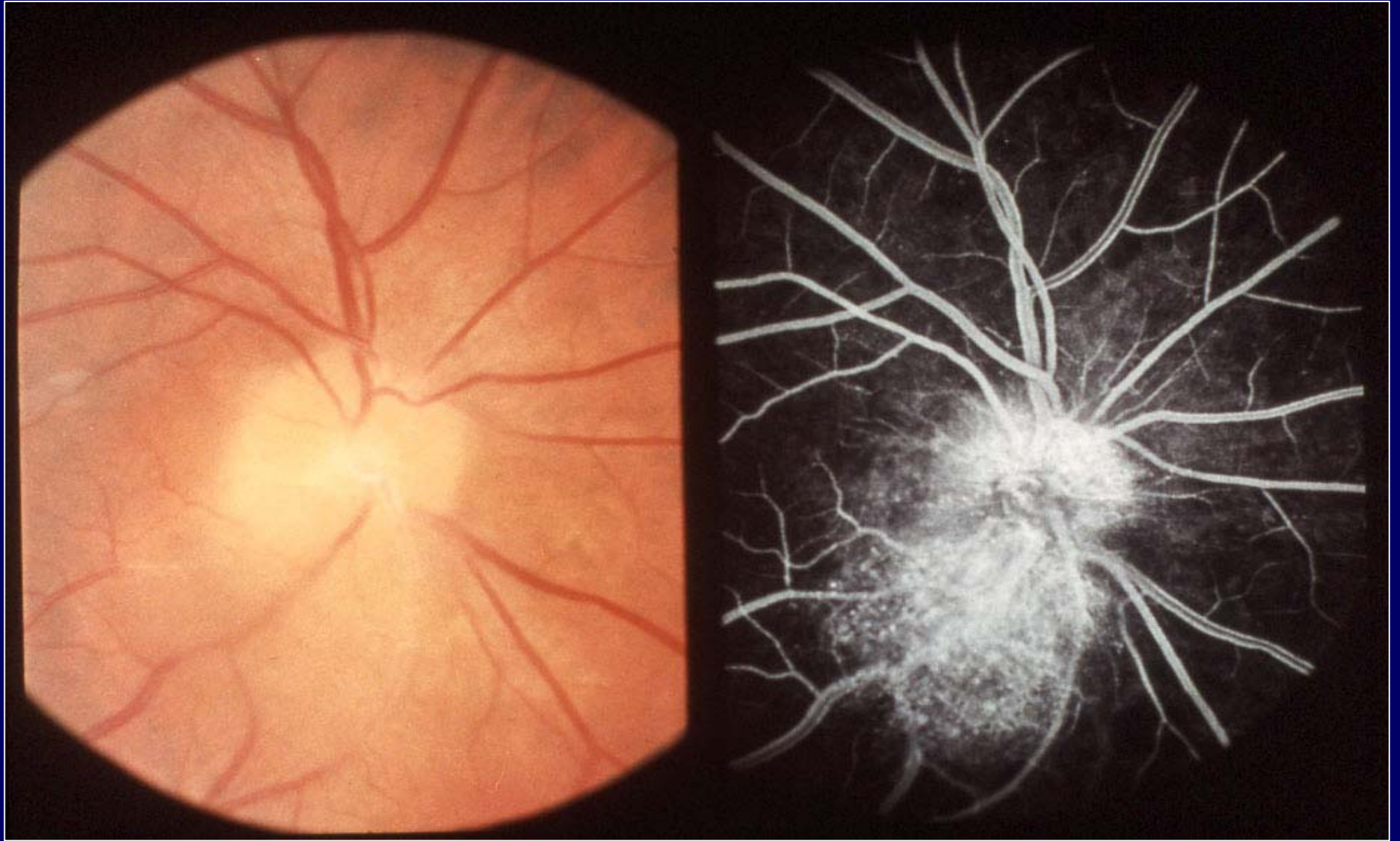


Pigmented epithelial hamartoma



Pigmented epithelial hamartoma:  
fluorescein angiogram





Capillary angioma of the optic disc